

ARTICLE IN REVIEW:

Greater risk of pseudarthrosis using PEEK spacers vs structural allograft in multi-level ACDF

PUBLICATION: Journal of Neurosurgery Spine, January 2020

TITLE: PEEK interbody devices for multilevel anterior cervical discectomy and fusion: association with more than 6-fold higher rates of pseudarthrosis compared to structural allograft.

AUTHORS: Teton ZE, Cheaney B, Obayashi JT, Than KD.

STUDY DESIGN: Retrospective, single center, multisurgeon, 81 patients.

SUMMARY: Anterior cervical discectomy and fusion (ACDF) is one of the most common treatments for cervical degenerative disc disease (CDDD). Long-term success depends on the placement of an interbody spacer to provide support and promote fusion. Structural bone allografts and synthetic polyetheretherketone (PEEK) are two of the most common interbody spacers used in ACDF. A previous study reported a 5-fold greater risk of pseudarthrosis using PEEK implants versus structural allografts in single-level ACDF.¹ This retrospective study evaluated the pseudarthrosis and reoperation rates in 81 consecutive patients who had undergone multi-level ACDF surgery using either structural allograft bone (n=46) or PEEK (n=35) interbody spacers. After at least 1-year follow-up, 26 out of 35 patients (74%) with PEEK implants demonstrated radiographic evidence of pseudarthrosis, which was 6.7-fold greater than that seen in patients with structural allografts (5 out of 46; 11%). Of these, 5 patients with PEEK implants (out of 26; 14%) required reoperation versus 0 patients with structural allografts. This study demonstrates a significantly greater risk of pseudarthrosis ($p<0.001$) and increased need for reoperation ($p=0.01$) with the use of PEEK interbody spacers in multi-level ACDF procedures compared to structural allografts. These results reinforce previous findings in single-level ACDF supporting the use of structural allografts in cervical fusion procedures.

Nearly 7-fold greater risk of pseudarthrosis with PEEK spacers in multi-level ACDF:

74% of patients with PEEK implants had radiographic pseudarthrosis compared to 11% of those with structural allografts.

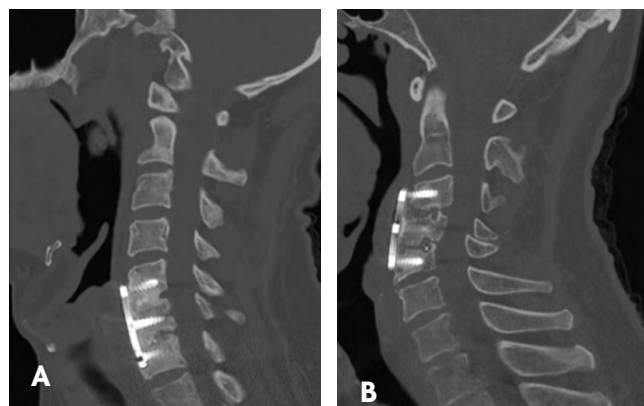
Higher reoperation rate with PEEK:

Of those with pseudarthrosis, 5 patients with a PEEK implant (14%) required revision surgery, compared to 0 patients in the structural allograft cohort.

Extends previous findings from single-level ACDF:¹

Further supporting use of structural allografts in cervical fusion procedures.

Greater risk of pseudarthrosis using PEEK vs structural allograft



Radiographs showing use of (A) structural allograft bone and fusion after 16 months and (B) PEEK interbody spacer and pseudarthrosis 43 months after surgery.

Reference

1. Krause KL, Obayashi JT, Bridges KJ, Raslan AM, Than KD. Five-fold higher rate of pseudarthrosis with polyetheretherketone interbody device than with structural allograft used for 1-level anterior cervical discectomy and fusion. J Neurosurg Spine 2019;30:46-51.

68-20-293.00

LifeNet Health and the LifeNet Health logo are registered trademarks of LifeNet Health. ©2020 LifeNet Health, Virginia Beach, VA. All rights reserved.

